

# UTILISATION OF COMPUTER BASED GUIDED SURGERY IN THE MANAGEMENT OF PARTIAL EDENTULISM

PATRICK HENRY<sup>1</sup>, JILL DEPIAZZI<sup>1</sup>, GLEN LIDDELOW<sup>1</sup>, BRENT ALLAN<sup>2</sup>, DAVID DUNN<sup>3</sup>

## Introduction

Recently, increased emphasis has been placed on the immediate loading of implants to simplify treatment and provide immediate function with minimal interference to patient lifestyle. A number of papers have concluded that implants rigidly connected across the midline offer survival rates comparable to that of implants loaded after a transitional healing period of several months. Whilst earlier studies focused on the symphyseal region of the edentulous mandible<sup>1-4</sup>, other studies have also demonstrated successful outcomes for the edentulous maxilla.<sup>5-8</sup> In the partially edentulous jaw only limited information exists as to the outcome of immediate loading, with early reports of encouraging short-term results.<sup>9,10</sup>

Further developments in this area have included the use of guided surgery protocols involving prefabrication on the basis of models derived from three dimensional implant planning software, of both surgical templates for flapless surgery and dental prostheses for immediate loading.<sup>11-12</sup> This Teeth-in-an-Hour™ concept (Nobel Biocare AB, Göteborg, Sweden) utilizes a CT scan derived customized surgical template for flapless surgery together with a prefabricated prosthetic superstructure and has proven to be a very reliable treatment option in selected cases.<sup>13</sup> Thus far, the majority of patients treated with this method have been edentulous in one or both jaws.<sup>14</sup>

*This paper is concerned with the application of guided surgery in the management of partial edentulism.*

## Case Selection

All of the standard inclusion and exclusion criteria pertinent to dental implants are applicable. Sufficient residual jaw bone must be present to house the implants adequately within bone. The procedure described is via a flapless approach, therefore bone quality must be sufficient to avoid perforation of the outer cortex during preparation of the installation site and subsequent engagement of soft tissue. An oral opening of 40mm in the incisor region is required for ease of instrumentation. The anterior region offers amenable access, however posteriorly, particularly in the mandible, difficulty can be encountered especially when the opposing arch is dentate.

<sup>1</sup> The Brånemark Centre, Perth, Western Australia

<sup>2</sup> Western Australian Centre for Osseointegration and Corrective Jaw Surgery, Perth, Western Australia

<sup>3</sup> Macquarie Street Centre for Implant and Aesthetic Dentistry, Sydney, New South Wales

Correspondence to: Patrick J Henry  
Level 1, 64 Havelock Street, West Perth WA 6005, Australia  
Telephone: +61 8 9321 7675, Facsimile: +61 8 9322 1119  
Email: patrick1@inet.net.au

## Treatment Planning Protocol

The sequential steps described for the edentulous jaw application<sup>15</sup> are identical for the partially dentate situation except that the fabrication of the template and guide are more technique sensitive because teeth are involved.

## Radiographic guide

A radiographic guide is fabricated on articulated study casts poured preferably from polyvinylsiloxane impressions so that the possibility of multiple casts exists. Acrylic resin denture teeth are set up on a radiolucent base of either light cured or autopolymerising acrylic resin. The teeth must fulfill esthetic expectations and functional requirements. Following patient acceptance of the set up, further material is added to cover the incisal edges of the existing dentition and to increase the occlusal vertical dimension in order to separate the teeth at the implant installation site. It is imperative that there is no cuspal or incisal overlap of the planned prosthetic teeth and the dentition of the opposing arch so that the replacement teeth can be clearly visualized radiographically. Several inspection

Figure 1: Fabrication of radiographic guide.

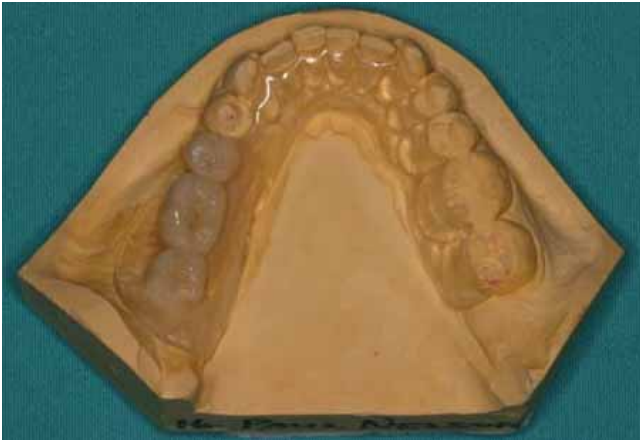

Figure 1a: Radiographic guide, occlusal view.

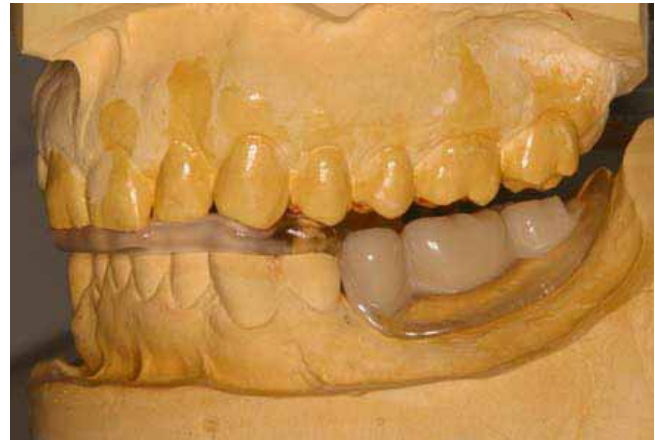

Figure 1b: Opening of occlusal vertical dimension to prevent tooth overlap.

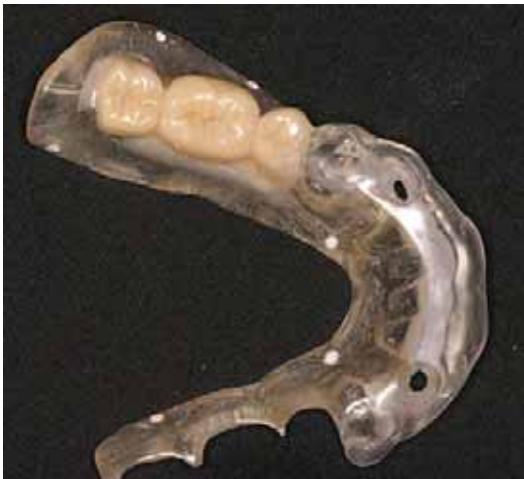

Figure 1c: Inspection windows and gutta percha markers.

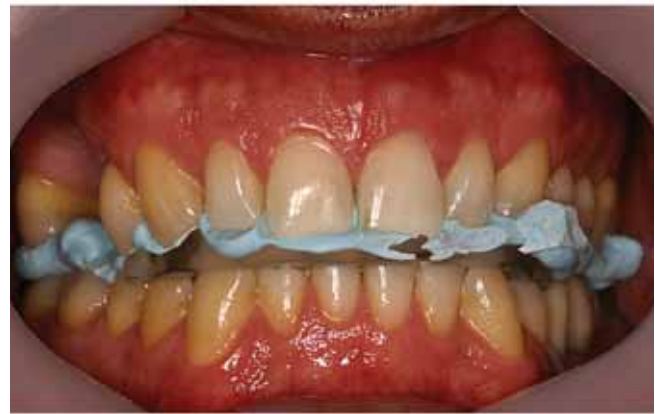

Figure 1d: Radiographic occlusal index.

windows are prepared in the occlusal aspect of the guide to confirm accurate seating of the device as illustrated in Figure 1. Six to eight 1-1.5mm diameter pieces of gutta percha are then placed strategically around the guide so that the device can be radiologically recognized in the subsequent CT examination. It is important that the denture base material be fully extended facially in the edentulous areas because the flange areas will be used to position anchor pins during the software planning. Finally an occlusal index is fabricated from radiolucent heavy bodied silicone rubber material as shown in Figure 1. This index is used to stabilise the guide during the CT scan procedures.

#### CT scan

A double scan technique is used whereby the first scan is taken with the radiographic guide in position whilst the second scan is taken only of the guide itself. Alteration of the CT technical specifications to reduce the radiation dose during the second scan permits the guide to be fully visible radiographically. The CT scans are then combined and converted into the 3D format

using NobelGuide™ Software (NobelGuide™ Clinical Premium, Nobel Biocare AB, Göteborg, Sweden). The software is then utilized to visualize and plan implant placement with simultaneous visualization of the prosthetic objective.

#### Implant treatment planning

The software is used to plan total implant treatment, firstly implant selection and predictable placement and secondly the design and type of prosthetic solution. The implant is surrounded by a 1.5mm safety zone which acts as an indicator of potential violation of adjacent vital anatomical structures such as tooth roots and the inferior dental nerve, as well as illustrating possible perforations of the bony envelope. Utilization of the software to plan a mandibular posterior situation is shown in Figure 2. The anchor pins are placed to avoid the implants and adjacent teeth. Preferably two pins are used to ensure good stabilization of the subsequent surgical guide and they should be positioned to minimize interference with lips and cheeks as well as to maximize surgical access for instrumentation.

## CLINICAL

Figure 2: Software planning sequence, implant placement.

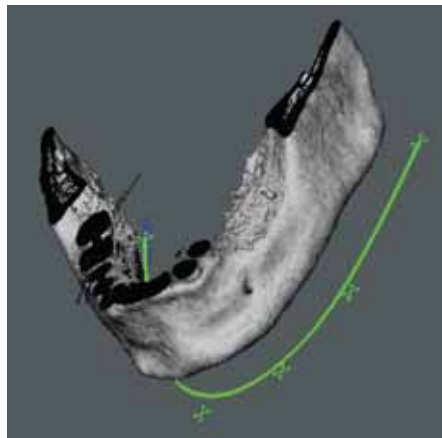


Figure 2a: Lateral view, posterior mandible.

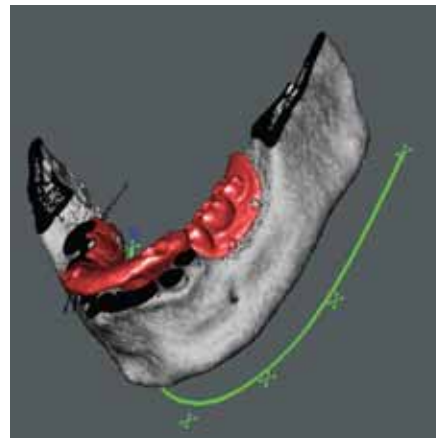


Figure 2b: Lateral view, posterior mandible, with radiographic guide.

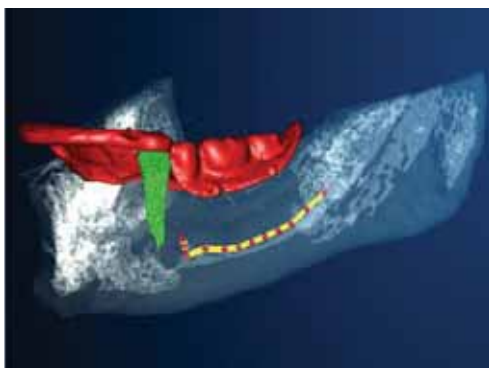

Figure 2c: Tracking of inferior alveolar dental nerve.

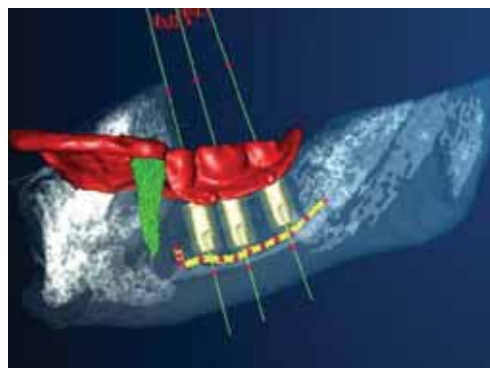


Figure 2d: Implant placement with safety zones.



Figure 2e: Positioning of anchor pins into template and between implants.

The occlusal location of the teeth is used in the planning process to orientate the inclination of the implants in a prosthetically driven manner. The available height between implant head and occlusal surface is measured to determine abutment type and prosthetic design, as seen in Figure 3. A minimum of 9mm is required for the use of Guided abutments (Nobel Biocare AB, Göteborg, Sweden) for a screw retained retrievable bridge. A minimum of 5 mm is required for the use of customized Procera® (Nobel Biocare AB, Göteborg, Sweden) zirconia abutments and cemented Procera® zirconia ceramic bridge. Situations with less than 5mm vertical space distribution can be planned to use smaller dimension abutments such as the 1mm MultiUnit Abutments™ (Nobel Biocare AB, Göteborg, Sweden) or planned for a screw retained prosthesis direct to implant level.

### Surgical template

The surgical template is manufactured industrially (Nobel Biocare AB, Göteborg, Sweden) using a sterolithographic process to produce the template in a medical grade plastic material with a 7-10 day turnaround time. Essentially, it is a replica of the radiographic template, containing sleeves to direct instrumentation and implant placement and anchor

pin sections for stabilization. The surgical template has two functions, firstly for implant placement and secondly for reconstitution of the master cast which is then used for fabrication of the prosthesis. The cast is produced as illustrated in Figure 4. The reconstituted cast is remounted on the articulator using the radiographic guide if insufficient teeth are present to adequately stabilize the occlusal

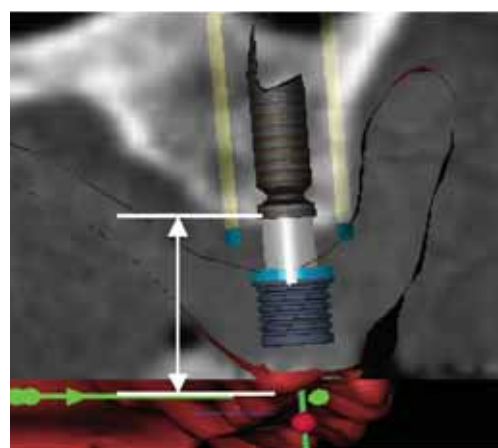
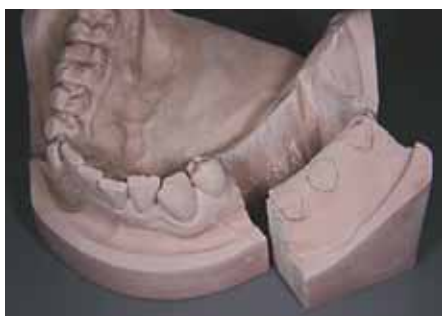

Figure 3: Measurement of occlusal-implant head dimension to determine available space for abutment type and prosthesis design.

## CLINICAL

**Figure 4: Reconstitution of master cast from the surgical template.**



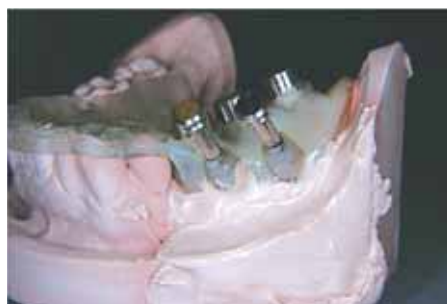**Figure 4a:** Duplicate master cast with residual ridge area removed.



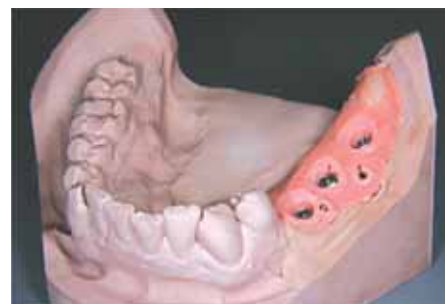**Figure 4b:** Retrofit of surgical template with implant laboratory analogues attached.



**Figure 4c:** Insertion of laboratory anchor pins and injection of rubber material to simulate soft tissue contours.



**Figure 4d:** Reconstitution of cast with diestone.



**Figure 4e:** Removal of anchor pins and surgical template from reconstituted cast.

position. The template is then tried in the mouth to assess stability using the inspection windows to determine accuracy of seating. A surgical occlusal index is prepared using a heavy bodied silicone rubber material. This index is important for template stabilization in the first step of the surgical protocol.

### Prosthesis manufacture

The reconstituted master cast is used to construct the planned prosthetic option, either retrievable screw retained Guided abutment bridge construction or a cemented bridge on customized zirconia Procera® abutments. Either solution may be definitive or provisional. Definitive screw retained prostheses utilize a Procera® titanium implant bridge framework veneered with either plastic crown and bridge material or titanium compatible ceramic material. Provisional screw retained prostheses are simply constructed with acrylic resin incorporating appropriate sleeves to anchor Guided abutments. Cemented solutions can utilize definitive Procera® zirconia frameworks veneered with NobelRondo™ zirconia porcelain or alternatively acrylic bridgework if a provisional procedure is planned. Examples of the different designs are shown in Figure 5 for a retrievable Teeth-in-an-Hour™ prosthesis and in Figure 6 for a cemented solution.

Alternatively pre-made prosthetic concepts can be dismissed and the treatment plan may be to install implants and then proceed with a surgical impression and fabrication of a provisional prosthesis utilizing traditional clinical and laboratory procedures and materials.

### Clinical procedures

In principle, protocol and sequencing is identical to that of the completely edentulous application.<sup>11,12</sup> Figure 7 illustrates the steps in clinical procedure. The number of anchor pins may be variable dependant on numbers of implants. In single missing tooth situations it may not be possible to place an anchor pin and in these cases the template is held in place by finger pressure with constant evaluation of the inspection windows to confirm accurate seating. Alternatively, palatally positioned anchor pin sites may be considered. The number of template abutments will also vary according to the number of implants. If three implants are to be installed generally the first one will be the centre one together with a template abutment. If two are to be placed generally the distal one is placed first together with a template abutment and careful observation of the anteriorly located inspection window to confirm accuracy of template position. Following prosthesis insertion, periapical radiographs are taken to confirm fit of the componentry. The occlusal scheme is designed and adjusted to be shim free in centric occlusion and to avoid or eliminate eccentric contact.

Post operative instructions emphasize that the restoration is to be considered an esthetic replacement in the first instance and is not to be used for heavy masticatory function for 6 weeks. Traditional implant follow-up and maintenance protocols are mandatory.

Single tooth indications present a limitation in planning and installation of implants as the software cannot guide the precise rotation of an external hex or internal trilobe. This means that some tweaking of the implant may be required to accurately establish proper alignment and orientation of

Figure 5: Retrievable prosthetic solution for Teeth-in-an-Hour™

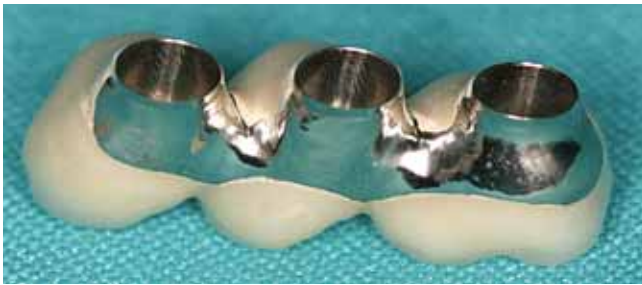

Figure 5a: Retrievable Procera® implant prosthesis with resin veneer, fitting surface.

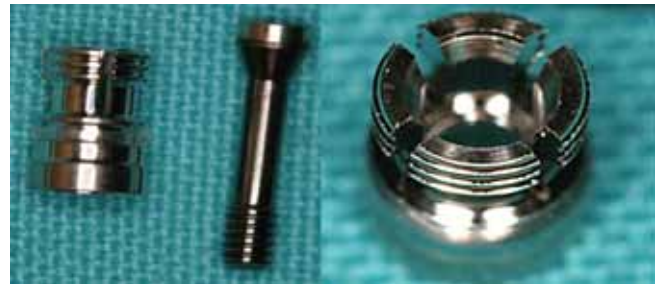

Figure 5b: 3D expandable Guided abutment.

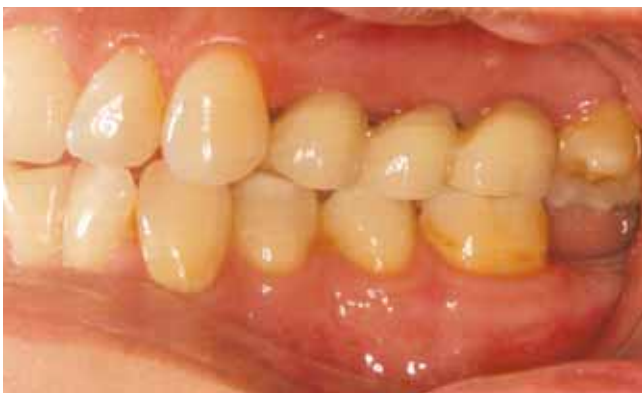

Figure 5c: Clinical appearance, buccal view.

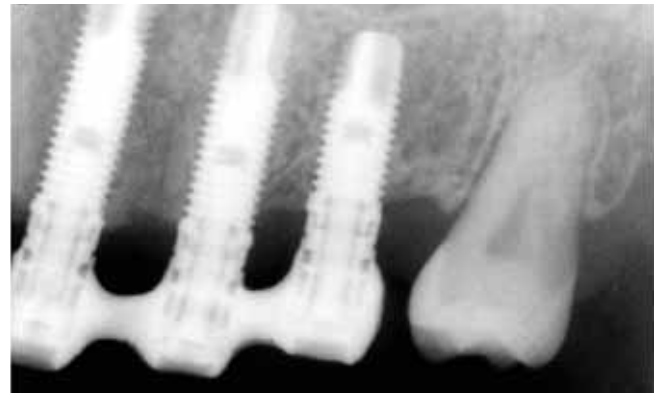

Figure 5d: Radiographic visualization of Guided abutments.

contact points of the pre-made crown fabricated on a reconstituted cast. Such minor repositioning of the implant is always done by advancing the implant because reversing it would jeopardise installation stability.

**Accuracy of the method**

The overall total error in dental implant guided surgery is an accumulation of the errors inherent not only to the reformatting of CT scan, software manipulations and template manufacture, but also to the multiple steps associated with

Figure 6: Cemented prosthetic solution for Teeth-in-an-Hour™

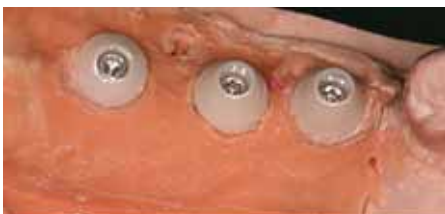

Figure 6a: Cast with zirconia abutments, lingual view.



Figure 6b: Tapered cylindrical design of abutments.

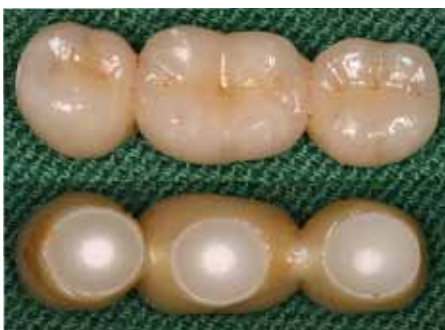

Figure 6c: Procera® zirconia cementable prosthesis, occlusal view and fitting surface.

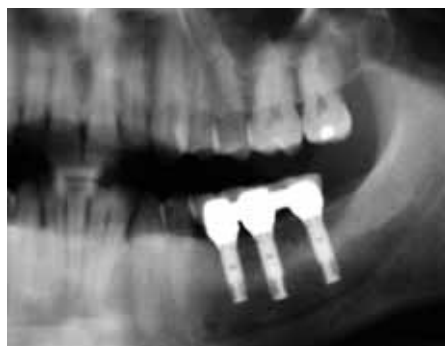


Figure 6d: Post operative panoramic radiograph.

clinical procedures. The original studies carried out by van Steenberghe et al<sup>11</sup> reported that difference between planned and achieved implant locations was on average  $0.8 \pm 0.3\text{mm}$  at the entry level and  $0.9 \pm 0.3\text{mm}$  at the target level. These differences were most prominent in the longitudinal direction of the implants with a maximum of 1.1mm. Finally the match between planned and actual implant axis was on average  $1.8 \pm 1.00$  degree. Clinically these discrepancies can be compensated two ways in the Teeth-in-an-Hour™ procedure. The guided abutment, visualized in Figure 5B is designed to have a 3D capability of adjustment as it is tightened, with built

in capability to adapt over and beyond the error dimensions discussed above. Alternatively the cemented solution compensates for the error by having the luting agent occupy the spatial error between abutment and prosthesis. It should be noted that the customized Procera® abutments are fabricated in a conical design so that rotational errors are irrelevant and only vertical discrepancy is significant. This is dependant on implants being installed within an axial inclination differential of 30°. Alternatively the clinician may decide not to use a reconstituted cast to fabricate the prosthesis, but instead to record an impression following implant insertion and employ traditional methods of prosthesis fabrication.

The sum total of dimensional error

## CLINICAL

Figure 7: Clinical Sequence, anterior maxilla.

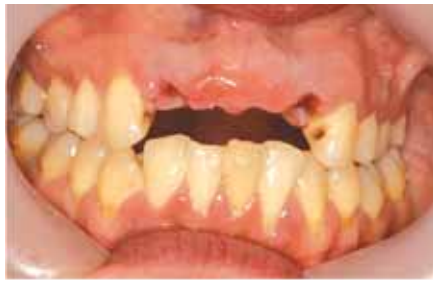

Figure 7a: Pre operative view following traumatic loss of 4 unit bridge placed on lateral incisors.

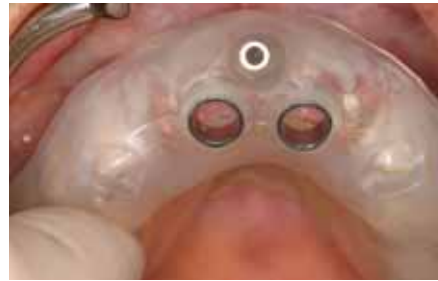

Figure 7b: Surgical Template.

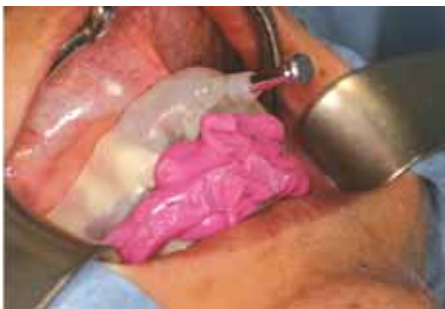

Figure 7c: Surgical index and anchor pin placement.

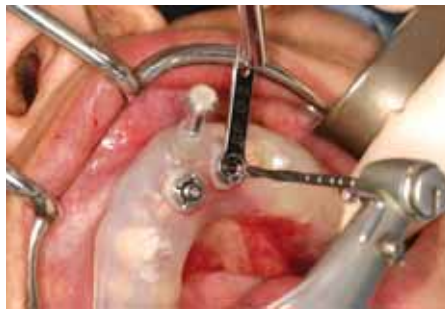

Figure 7d: Instrumentation sequence with right template abutment placed.

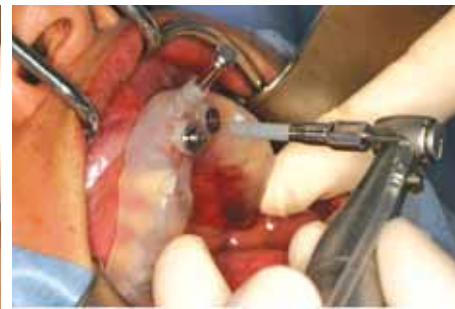

Figure 7e: Installation of second implant.

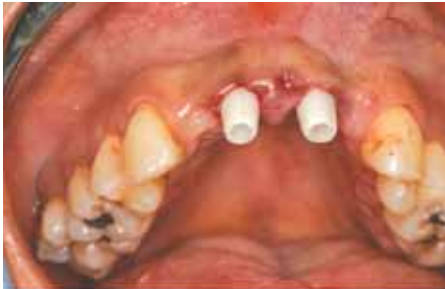

Figure 7f: Template removal and insertion of zirconia abutments.

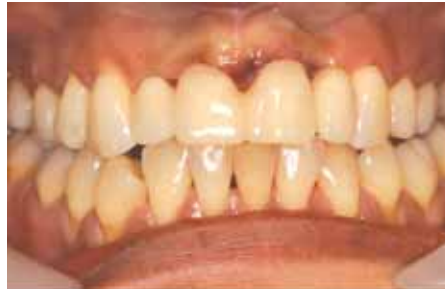

Figure 7g: Provisional cemented prosthesis in acrylic resin.

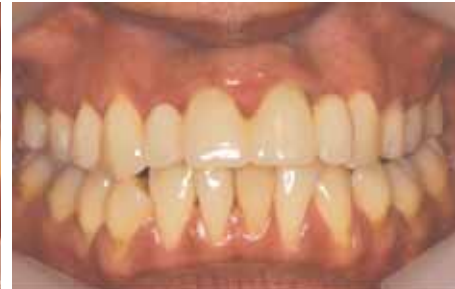

Figure 7h: 6 month follow-up prior to commencement of definitive prosthetics.

associated with clinical procedures including impressions and occlusal records as well as laboratory phases of articulator mountings etc together with the various dimensional changes associated with dental materials involved of course result in discrepancies similar to those inherent in traditional crown and bridgework methodology. Notwithstanding these considerations however, it must be emphasized that the single most crucial consideration in the overall accuracy of the method is in fact the positioning and precision of the radiological guide. This device is fundamental to the provision of the planning data and manufacture of the surgical template.

### Clinical applications of guided surgery

NobelGuide™ is a total concept offering flexibility and broad application. Figure 8 illustrates the possibilities. It may be used only as a treatment planning tool to evaluate and determine implant installation sites by clinicians using the traditional methods for the planning and execution of implant treatment. It may be taken a step further to the stage of surgical template with the template used only for implant installation. Following the surgical phase traditional methods may then be employed

to either place healing abutments as a single stage surgical procedure or to take an implant or abutment level impression and proceed with a provisional or definitive restoration when convenient. This procedure eliminates all considerations of the error of the method and furthermore gives the clinician the opportunity, if required, to carry out adjustments in implant position with respect to depth of installation and relationship to the marginal bone and soft tissue levels.

Alternatively the surgical template may also be used to reconstitute a master cast to fabricate prosthetic solutions that are either definitive or provisional and either screw retained or cemented, thus encompassing the Teeth-in-an-Hour™ concept. The decision making process with respect to pathways, either definitive or provisional, is based on a consideration of several factors. Final pathway Teeth-in-an-Hour™ restorations offer minimal flexibility and higher risk in esthetically demanding situations. Provisional pathway restorations offer the advantages of giving the clinician and patient time to evaluate esthetic and functional results particularly in situations of high esthetic demand, thus facilitating the opportunity to satisfy patient expectations. Thus flexibility is maximised, stress is reduced and the necessity to remake final restorations

## CLINICAL

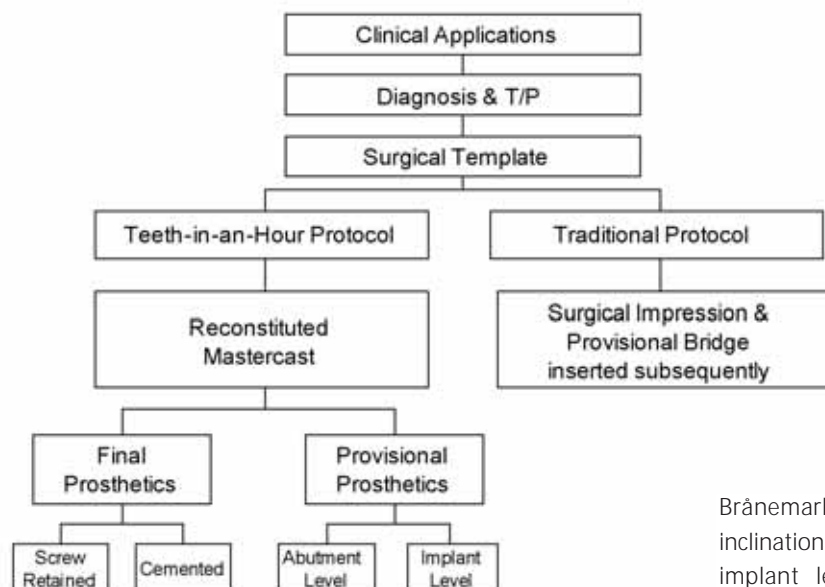


Figure 8: Clinical application of NobelGuide™

minimised. These advantages are further enhanced in situations requiring secondary soft tissue manipulations in high end esthetic cases.

### Results

The outcome of the first 13 prostheses placed in 10 consecutive patients with a follow-up time of 12-24 months is shown in Table 1. The patients ranged in age from 35 – 57 with two of the patients being male. 34 implants were placed to support 16 partially edentulous bridges and 2 missing single teeth. The implant types and dimensions employed are described in Table 2.

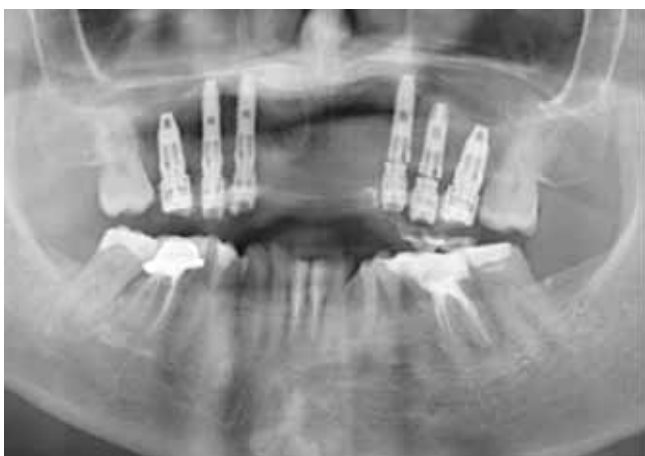One prosthesis failed to seat adequately in a posterior maxillary location with very soft bone type (Case 4). It was concluded that one implant had been installed off centre because the implant mount was difficult to remove from the template indicating that it was off centre on the hex of the

Brånemark implant used relative to the guide sleeve inclination. Therefore the prosthesis could not be inserted. An implant level impression was taken and the treatment subsequently completed using traditional methods of fabrication.

Two implants failed. In Case 7 the distal implant (Brånemark System® 15mm long RP) of the three unit splinted design failed 6 month postoperatively. The situation was asymptomatic and the failure was detected by stability assessment at follow-up. The implant was removed, and immediately replaced with a wider diameter implant and single stage surgery. It was left to heal for 4 months and then the prosthetic work remade.

The second implant (NobelReplace® Tapered 8mm WP) failed in a bilateral posterior mandibular partially edentulous patient where considerable difficulty was experienced with instrumentation access (Case 12). 4 months post-operatively the patient developed discomfort in the left posterior region and prosthesis removal revealed failure of the distal implant. It was separated from the bridge, removed and left to heal. The shortened prosthesis was replaced on the two anterior implants as an interim measure. The failed implant was replaced 3 months later with single stage surgery. The bridge was successfully remade 5 months later. Thus the cumulative survival rate of the implants placed using Teeth-in-an-Hour™

Figure 9: Failure to seat Teeth-in-an-Hour™ provisional bridge.



9a: Post operative panoramic radiograph showing ill fitting prosthesis on 2 implants. This requires immediate removal and retrofit of the deficient Guided abutments to prevent overload of adjacent implants.

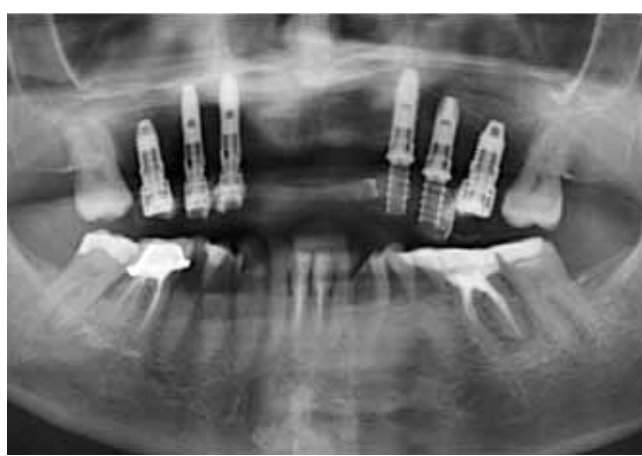

Figure 9b: Retrofit of temporary abutment cylinders at sites of deficient abutments and reconstitution of the provisional bridge.

**Table 1 – Patient Implant – Prostheses Specifications**

Case Number	Patient Number	Prosthesis Type	Prosthesis Location	Number of Implants	Implant Type	Immediately Loaded	Implant Failures	Follow-up Months
1	1	splinted crowns	posterior mandible	3	Brånemark System®	Yes	-	24
2	2	4 unit bridge	anterior maxilla	2	Brånemark System®	Yes	-	22
3	3	4 unit bridge	posterior maxilla	3	NobelReplace™	Yes	-	22
4	4	splinted crowns	posterior maxilla	2	Brånemark System®	No	-	22
5	5	3 unit bridge	posterior maxilla	2	Brånemark System®	Yes	-	21
6	6	splinted crowns	posterior maxilla	3	Brånemark System®	Yes	-	21
7	7	splinted crowns	posterior maxilla	3	Brånemark System®	Yes	1	20
8	7	splinted crowns	posterior maxilla	3	Brånemark System®	Yes	-	20
9	8	single tooth	anterior maxilla	1	NobelReplace™	Yes	-	18
10	8	single tooth	anterior maxilla	1	NobelReplace™	Yes	-	18
11	9	splinted crowns	posterior mandible	2	NobelReplace™	Yes	-	17
12	9	splinted crowns	posterior mandible	3	NobelReplace™	Yes	1	17
13	10	10 unit bridge	anterior maxilla	6	NobelSpeedy™ Tapered	Yes	-	12
<b>13</b>	<b>10</b>	<b>13</b>	<b>34</b>				<b>2</b>	
Cumulative Survival Rate = 94.1%								

protocol was 94.1%.

### Advanced considerations

#### Maintenance of keratinised tissue

NobelGuide™ is fundamentally a flapless procedure using a punch technique whereby a section of keratinized tissue is lost. This is of concern to some clinicians in critical esthetics areas or in locations that could benefit by soft tissue augmentation. In these instances the protocol can be amended to placement of the template with anchor pins followed by removal of the template. A flap is then raised, either mid-crestal or palatally situated and reflected following which the template is reinserted and the drilling sequence commenced. Soft tissue augmentation procedures can be performed concurrently if required. This approach provides clinicians with the advantages of controlled and precise implant placement, together with the flexibility of soft tissue manipulation and conservation of tissue.

#### Simultaneous bone grafting

In these situations the surgical template is inserted and anchor pins positioned. It is then removed to permit a lingualised incision followed by flap reflection beyond the labial periphery of the template. The template is then reinserted with anchor pins repositioned. Implant placement is carried out, template removed and bone grafting augmentation completed. The situation is then managed as a 2 Stage procedure.

#### Guided surgery with simultaneous extraction

This can be utilised in selected cases but requires careful consideration, both technically and clinically. The implant installation guide sleeve incorporated in the template must be of greater dimension than the corresponding tooth root

dimension in the proposed extraction installation site to ensure implant stability. This in principle rules out most molar sites. It must also be emphasized that this procedure is unpredictable in terms of the resultant bony envelope after extraction of the tooth and the subsequent remodeling of the marginal hard and soft tissues. Therefore it is often contraindicated in the esthetic zone. Nevertheless, there is a clinical demand for such procedures and appropriate protocols are currently under evaluation in clinical trials.

#### Problems and complications

The problems and complications associated with immediate loading of dental implants using traditional methods are applicable to guided surgery and immediate loading. However, there are additional complications inherent to guided surgery that deserve consideration. The commonest problems are all related to protocol violation resulting in surgical template inaccuracy. The use of an inadequate number of radiological markers in the radiographic guide can result in malpositioning of the surgical template which is quite distinct from an inherently unstable or inaccurate radiological guide.

Insertion of template abutments requires careful attention to tightening force because a template can be deformed with application of excessive pressure. Care must be taken at implant installation to ensure that implant insertion is absolutely central and vertical to the guide sleeve inclination, otherwise the implant may be positioned off centre with or without jamming of the implant mount within the guide sleeve. These errors may be reflected in failure to seat the prosthesis as evident in Figure 9. If cases are planned without reference to prosthetic componentry dimension and the available space between occlusal level and implant head level,



## CLINICAL

Table 2 – Implant Types

Brånemark System®			NobelReplace™			NobelSpeedy™ Replace		
Length	3.75mm ø	4.00mm ø	Length	4.3mm ø	5mm ø	Length	4.00mm ø	5.00mm ø
10		1	8		1	10		2
11.5		1	10		3	13	1	
13		4	13	3		15	3	
15	6	6	16	3		18		
	6	12		6	4		4	2
	18			10			6	
<b>34</b>								

gross occlusal interference can result at prosthesis placement.

A fundamental tenet of prosthodontic discipline is that the original master cast should be maintained in the patient records and duplicates used for all laboratory work stages. In the event of a production line accident involving irreversible damage to the master cast, retrofitting a radiological guide or surgical template accurately may mean that the sequencing goes back to the start resulting in the CT scan and reformat diagnostic data becoming useless. Consequently the patient must receive additional and not insignificant radiation to redo the CT scan. Furthermore the clinician has to absorb the costs of manufacture of the additional surgical template.

On receipt, surgical templates may require adjustment to fit the cast accurately. Again the source of additional working casts to retrofit the template in the laboratory is dependant of the availability of a master cast for duplication. Templates may be manufactured where the thickness of plastic material around the guide sleeves results in failure to seat because of contact point interference. This additional thickness is a result of CAD/CAM manufacture where the dimension of material for strength and support reasons during construction of the template is industrially controlled and automatic. This problem can be offset by ensuring that the mesio-distal dimensions of the residual alveolar ridge is sufficient to accommodate the dimensional requirements of guide sleeve and plastic support where possible.

In the posterior regions limited mouth opening may prevent placement of instrumentation which is of increased length to accommodate the dimensions of the template guide sleeve. This can be sometimes overcome by assembling the instrumentation into the template extra-orally and then reinserting the combined template and drilling instrumentation simultaneously. Whilst this is more onerous and time consuming, it may avoid abandoning the procedure.

In immediate loading protocols, a fallback position strategy should be employed in treatment planning as it is possible to place an implant that has insufficient primary stability for immediate loading. The fallback strategy is to either place healing abutments, or remove the implant and install a larger dimension implant. If the case at hand is a Teeth-in-an-Hour™

situation it means that the procedure must be aborted, however the fallback position could be to convert the treatment plan to implant placement, surgical impression and traditional pathway provisional prosthesis.

### Discussion

Experience with guided surgery and immediate loading is limited in the partially edentulous application and the evidence base is sparse. As yet, no five year study results have been reported, and current studies are only short-term with results yet to be reported. However, the limited short-term results reported in this paper do compare favourably with the results reported for both partially edentulous bridge patients<sup>16</sup> and single tooth applications<sup>17</sup> using the traditional 2 stage surgery protocol after 1-2 years of loading. Our cumulative survival rate of 94.1% is similar to that reported in the multicentre partially edentulous jaw study (94.3%)<sup>16</sup>. In the multicentre single tooth study a success rate of 97.2% was reported<sup>17</sup>, but this did not include any implants placed in the posterior maxilla, which is an area of soft bone quality and higher failure rate. Only 2 single tooth implants were placed in this study, both successful after 1-2 years of loading. Thus the results of this study are encouraging. Furthermore patient demand for immediate function solutions is increasing.

Patient benefits include maximized comfort with minimal invasiveness, pain and post operative swelling. Dentist benefits include increased predictability in planning and increased safety in implementation. Difficulty in assessing the primary stability of implants can be experienced in guided surgery because tactile sensibility is offset by the influence of the template guide sleeve. Insertion torque can be unreliable because of frictional resistance of the implant mount against the guide sleeve particularly where access is difficult and compromised. Resonance frequency analysis has been used to differentiate successful and failing implants placed into immediate or early functional loading.<sup>18</sup> We have found that this modality can be a useful adjunct in assessing implant stability following removal of the surgical guide. This modality measures implant stability electronically and the result is interpreted as an implant stability quotient (ISQ) on a scale of

0-100. (Osstell, Integration Diagnostics, Sävedalen, Sweden) In our experience a measurement of ISO 60 is subjectively used as the lower limit for immediate loading where occlusion is favourable. In the event that this is not attained, the protocol reverts to a fallback strategy of delayed loading as can occur in situations of poor bone quality or compromised installation.

The pre-production of a prosthesis and the Teeth-in-an-Hour™ concept is a realistic possibility in selected cases. Nevertheless, the majority of clinicians favour the provisional pathway concept because of flexibility in prosthetic outcome, particularly in esthetically demanding cases. NobelGuide™ is seen to be a global rehabilitation concept offering potential for a range of clinical solutions. It is universally applicable as a planning tool in all implant cases.

### Conclusion

Guided surgery with immediate loading of implants is possible in the partially edentulous situation in selected cases. NobelGuide™ is a CT scan related global concept with universal applications for diagnosis and treatment planning. An industrially derived surgical template can be provided for the predictable and safe placement of implants and can be further used to reconstitute a cast for the pre production of various prosthetic solutions. Implants placed using this modality demonstrate similar survival rates to those placed using traditional protocols.

### Acknowledgement

The authors gratefully recognize the encouragement and expertise of Dr Matts Andersson for his efforts in making the treatment of the patients discussed in the paper possible.

### References

1. Schnitman PA, Wöhrle PS, Rubenstein JE, Da Silva JD, Wang NH. Ten-year results for Brånemark implants immediately loaded with fixed prostheses at implant placement. *Int J Oral Maxillofac Implants* 1997;12:495-503.
2. Tarnow DP, Emtiaz S, Classi A. Immediate loading of threaded implants at stage 1 surgery in edentulous arches: ten consecutive case reports with 1- to 5-year data. *Int J Oral Maxillofac Implants* 1997;12:319-324.
3. Ganeles J, Rosenberg MM, Holt RL, Reichman LH. Immediate loading of implants with fixed restorations in the completely edentulous mandible: report of 27 patients from a private practice. *Int J Oral Maxillofac Implants* 2001;16:418-426.
4. Becker W, Becker BE, Huffstetler S. Early functional loading at 5 days for Brånemark implants placed into edentulous mandibles: a prospective, open-ended, longitudinal study. *J Periodontol* 2003;74:695-702.
5. Horiuchi K, Uchida H, Yamamoto K, Sugimura M. Immediate loading of Brånemark System implants following placement in edentulous patients: a clinical report. *Int J Oral Maxillofac Implants* 2000;15:824-830.
6. Olsson M, Urde G, Andersen JB, Sennerby L. Early loading of maxillary fixed cross-arch dental prostheses supported by six or eight oxidized titanium implants: Results after 1 year of loading, case series. *Clin Implant Dent Relat* 2003;5(Suppl 1):81-87.
7. Fischer K, Stenberg T. Early loading of ITI implants supporting a maxillary full-arch prostheses: 1 year data of a prospective, randomized study. *Int J Oral Maxillofac Implants* 2004;19:374-381.
8. Gallucci G, Bernard JP, Bertosa M, Belsler U. Immediate loading with fixed screw-retained provisional restorations in edentulous jaws: The pickup technique. *Int J Oral Maxillofac Implants* 2004;19:524-533.
9. Glauser R, Lundgren AK, Gottlow J, Sennerby L, Portmann M, Ruhstaller P, Hämmerle CH. Immediate occlusal loading of Brånemark TiUnite™ implants placed predominately in soft bone: 1-year results of a prospective clinical study. *Clin Implant Dent Relat Res* 2003;5(Suppl 1):47-56.
10. Rocci A, Martignoni M, Gottlow J. Immediate loading in the maxilla using flapless surgery, implants placed in predetermined positions, and prefabricated provisional restorations: a retrospective 3-year clinical study. *Clin Implant Dent Relat Res* 2003;5(Suppl 1):29-36.
11. van Steenberghe D, Naert I, Andersson M, Brajnovic I, Van Cleynenbreugel J, Suetens P. A custom template and definite prosthesis allowing immediate loading in the maxilla: A clinical report. *Int J Oral Maxillofac Implants* 2002;17:663-670.
12. van Steenberghe D, Glauser R, Blombäck U, Andersson M, Schutysen F, Pettersson A, Wendelhag I. A computed tomographic scan-derived customized surgical template and fixed prosthesis for flapless surgery and immediate loading of implants in fully edentulous maxilla: A prospective multicentre study. *Clin Implant Dent Relat Res* 2005;(Suppl 1) S111-S120.
13. Kupevan HK, Shaffner M, Armstrong J. Definitive CAD/CAM-guided prosthesis for immediate loading of bone-grafted maxilla: a case report. *Clin Implant Dent Relat Res* 2006;8:161-167
14. Balshi SF, Wolfinger GJ, Balshi TJ. Surgical planning and prosthesis construction using computed tomography, CAD/CAM technology, and the Internet for immediate loading of dental implants. *J Esthet Restor Dent* 2006;18:312-323
15. Marchack CB. An immediately loaded CAD/CAM-guided definitive prosthesis: A clinical report. *J Prosthet Dent* 2005;93:8-12.
16. Henry PJ, Tolman DE, Bolender C. The applicability of osseointegrated implants in the treatment of partially edentulous patients: Three year results of a prospective multicentre study. *Quintessence Int* 1993;24:123-129.
17. Laney W, Jemt T, Harris D, Henry PJ, Krogh PH, Polizzi G, Zarb GA, Herrmann I. Osseointegrated implants for single tooth replacement: Progress report from a multicentre prospective study after 3 years. *Int J Oral Maxillofac Implants* 1994;9:49-54.
18. Glauser R, Sennerby L, Meredith, et al. Resonance frequency analysis of implants subjected to immediate or early functional occlusal loading. Successful vs. failing implants. *Clin Oral Implants Res* 2004;15:428-434.